

# Malignant Melanoma Arising in an Ovarian Mature Cystic Teratoma - A Rare Entity

RANJINI KUDVA<sup>1</sup>, GAURI SALGAONKAR AYACHIT<sup>2</sup>, ANURAG AYACHIT<sup>3</sup>

## ABSTRACT

Mature cystic teratomas, also known as dermoid cysts, are composed of a mixture of tissues derived from all three germ layers and constitute about 20% of all ovarian neoplasms. However, malignant transformation in a mature cystic teratoma is an uncommon event occurring only in about 1.8% cases. A variety of tumours can arise within a mature cystic teratoma (most common being squamous cell carcinoma), with malignant melanoma being extremely rare among such tumors. While most authors believe that primary ovarian melanoma almost always arises within a mature cystic teratoma, the primary nature of an ovarian malignant melanoma can be ascertained only once metastasis from a cutaneous melanoma is ruled out. The first case of malignant melanoma arising in an ovarian mature cystic teratoma was reported in 1901 and only about 45 additional cases have been reported till date. We present another case of a primary malignant melanoma arising within a mature cystic teratoma.

**Keywords:** CA19.9, CA125, CEA, HMB-45, Ovarian dermoid cyst, Ovarian malignant melanoma

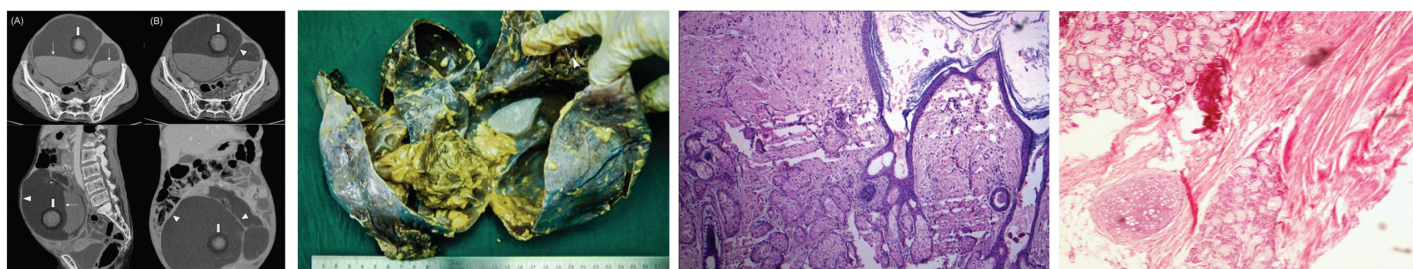
## CASE REPORT

A 56-year-old woman, post-menopausal for 12 years, presented with gradually enlarging palpable abdominal mass over one year, loss of appetite, abdominal distension and early satiety, without any vaginal discharge or post-menopausal bleeding. Physical examination revealed a lower abdominal bosselated mass corresponding to 24 week uterus size. Per vaginum, a mass was felt in the left fornix, right fornix was free. Ultrasound showed a mixed echogenicity solid-cystic abdominopelvic mass with thin septations. Computed tomography [Table/Fig-1] revealed a large multiloculated solid-cystic abdominopelvic mass (19.6x13.9x16.2cm) with areas of fat attenuation and fat fluid levels suggestive of teratoma. Ovaries were not separately visualised. Ascites was absent. Biochemical investigations revealed elevated tumour markers CA19.9 (102 U/ml), CEA (4.3 ng/ml) and CA125 (398.7 U/ml). Laparotomy revealed a right ovarian mass. Total abdominal hysterectomy was performed with bilateral salpingo-oophorectomy, pelvic lymph node sampling, infracolicomentectomy and appendicectomy. There was no obvious evidence of metastatic disease.

On gross examination, the tumour was cystic with a smooth wall. Cut section [Table/Fig-2] revealed multiple cystic areas

containing pultaceous material with hair shafts, few whitish specks of calcification and a small solid blackish nodular area (1.0x0.5 cm). Left ovary revealed normal ovarian parenchyma. Microscopy revealed cystic areas lined by epidermis-like keratinised stratified squamous epithelium and underlying fibrocollagenous stroma with pilosebaceous units [Table/Fig-3] cyst macrophages with lymphoplasmacytic infiltrates, adipose tissue, ganglion cells, cartilage, pigment, smooth muscle, pancreatic acini, gastric mucosa, calcification and nerve fibres [Table/Fig-4]. The blackish nodular focus was composed of lobules and nests [Table/Fig-5] of polygonal cells with pleomorphic vesicular nuclei, prominent eosinophilic nucleoli, mitotic figures, intranuclear inclusions, abundant eosinophilic cytoplasm with focal melanin pigment [Table/Fig-6] and stromal necrosis. Since cytological features and abundant melanin pigment were strongly suggestive of melanoma, a provisional diagnosis of melanoma arising within a teratoma was made and confirmed on immunohistochemistry, which was positive for HMB-45 [Table/Fig-7]. Staining with other markers was not deemed necessary.

Reevaluation for the presence of a primary malignant melanoma elsewhere (skin, CNS and eyes) was negative. Post-operatively she

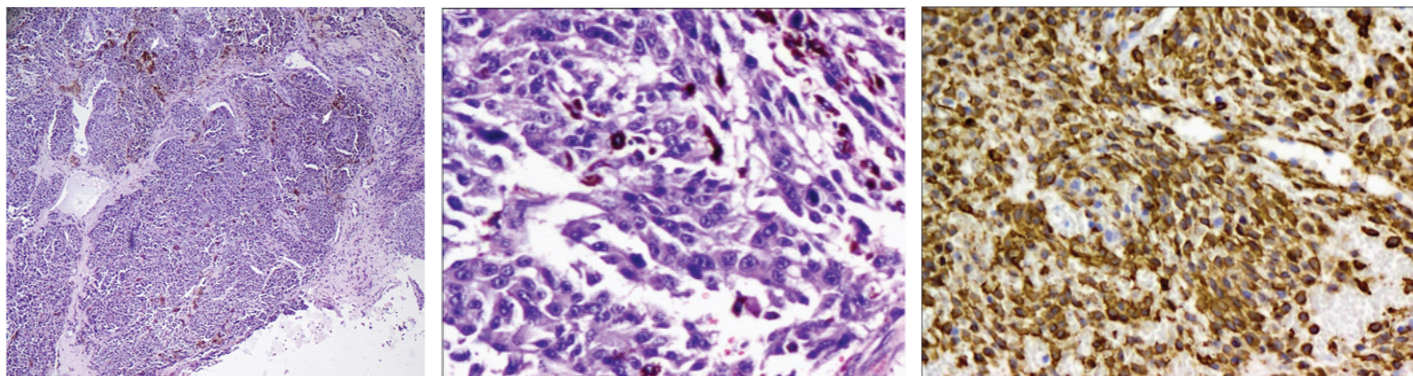


**[Table/Fig-1]:** Plain (A) and post-contrast axial (B), sagittal (C) and coronal (D) images CT images show a large well defined multiloculated solid-cystic mass arising from right side of pelvis extending into abdomen with smooth enhancing wall (arrowheads) and internal septations (arrowheads) with few specks of calcifications. Lumen shows fluid-fluid levels (thin arrows) with a rounded fat attenuation area (thick arrow) within

**[Table/Fig-2]:** Cut section of right cystic ovarian mass with smooth outer wall and attached tube, multiple cysts filled with pultaceous material and hair follicles and a blackish solid nodular area (arrowhead). The small specks of calcification were too small to be visualised on photograph

**[Table/Fig-3]:** Low power (100x) microscopy with H&E staining: Cyst wall lined by stratified squamous epithelium with pilosebaceous glands in the wall

**[Table/Fig-4]:** High power (200x) microscopy with H&E staining: Cyst wall showing cartilage, adipose tissue, gastric mucosa and smooth muscle



**[Table/Fig-5]:** Low power (100x) microscopy with H&E staining: nests of melanoma cells with melanin pigment (arrow)

**[Table/Fig-6]:** High power (200x) microscopy with H&E staining: Solid area showing large polygonal cells with vesicular nuclei, prominent nucleoli and melanin pigment

**[Table/Fig-7]:** High power (400x) immunohistochemistry: HMB positivity of tumor cells

received four cycles of chemotherapy and was disease free till last follow-up.

## DISCUSSION

Ovarian teratomas are composed of cellular elements derived from all three germ cell layers, all of which are capable of giving rise to malignant tumours, though this occurs only in 0.17-2% cases [1]. A wide spectrum of malignant tumours are documented, commonest being squamous cell carcinoma (88.3%), followed by adenocarcinoma, fibrosarcoma, carcinoid tumour and mixed tumours [2]. Malignant melanoma arising in an ovarian teratoma is a rare event with an estimated incidence of 0.2-0.8% [3].

Most ovarian melanomas represent metastasis from a known melanoma elsewhere [4], with 77 such cases reported till date [5] and asymptomatic ovarian metastasis reported in up to 18% autopsies [6]. Most cases labeled as primary ovarian melanoma represent metastasis from an unknown primary or a primary melanoma which was excised or underwent spontaneous regression [5,7]. Forty-five cases of primary melanoma arising in mature cystic teratoma have been reported [8]. Our review of literature showed that the diagnosis of a primary ovarian melanoma arising from ovarian parenchyma (in absence of a dermoid cyst) may be exceedingly rare, to the extent that no such cases have been explicitly reported so far.

Primary malignant melanoma within an ovarian dermoid cyst was reported first by Andrews in 1901 [9]. Dermoepidermal junctional activity was not observed in our case, similar to a review by Ueda et al., who found it in only 50% of the cases [10]. This may be explained by the fact that a melanoma may originate from any melanocyte containing component of an ovarian dermoid such as meningeal or uveal epithelium, as opposed to cutaneous melanomas that essentially arise from the dermoepidermal junction. Alternately, other benign pigmented lesions (nevus or pigmented schwannoma) may also give rise to a malignant melanoma [10]. Finally, tumour invasion itself may destroy the dermoepidermal junction from which it arises.

The presence of a blackish solid nodular area within the dermoid on gross examination and microscopic features characteristic of melanoma (pleomorphic vesicular nuclei, prominent eosinophilic nucleoli and intranuclear inclusions) in our patient supported the diagnosis of malignant melanoma arising in a teratoma. Immunohistochemically, the tumour cells were positive for HMB-45, a specific marker for melanoma, thus confirming the diagnosis. Melanoma tumour cells may also be positive for S-100, MART-1, Tyrosinase, Melan-A [4,5,11], C-kit and PTEN [8].

Our case was labelled as primary ovarian melanoma as it meets most of the criteria proposed by Boughton et al., [12] viz., it was unilateral, associated with an ovarian teratoma, with no evidence of demonstrable extraovarian melanoma and there was good

correlation of patient's age and symptoms (post-menopausal female with a long-standing gradually enlarging abdominal mass) with the documented cases in the past. It has been proposed that the possibility of melanoma arising in ovarian cystic teratoma is high when associated with elevated serum levels of CA19.9 [2]. Our patient had elevated serum CA19.9, and further, ours is the only case associated with elevated levels of CEA and CA125 as well, not documented previously. Hence, proper identification of histologic features aided by melanocytic markers is important for making the right diagnosis.

The clinical, radiologic and per-operative diagnosis was dermoid cyst, confirmed on histopathologic examination, with only a small incidental melanoma component. While there are no specific differential diagnoses for the former lesion, sex cord stromal tumors and steroid cell tumours (both having cells with abundant eosinophilic cytoplasm) are the differential diagnoses for ovarian melanoma. However, in our case, the cytological features, focal melanin pigment and immunohistochemical positivity for HMB45 along with a negative survey for melanoma elsewhere confirmed the diagnosis of a primary ovarian melanoma.

The treatment of choice for ovarian malignant melanoma is hysterectomy with salpingo-oophorectomy and pelvic clearance followed by chemotherapy. Although primary ovarian melanomas are associated with very poor prognosis similar to melanomas arising at other unusual sites, chemotherapy with drugs like cisplatin, dacarbazine and temozolomide have prolonged the survival in some cases [3]. Recent studies have also highlighted the importance of immunotherapies and targeted therapies for the treatment of malignant melanomas. Compared to ovarian carcinoma, patients with ovarian melanoma at similar stage have a worse prognosis [2]. Ovarian melanomas metastasize locally to adjacent structures or by hematogenous or lymphatic routes to the liver, lung and bones [2]. Our case had no such metastasis.

## CONCLUSION

Malignant melanoma arising in an ovarian mature cystic teratoma is exceedingly rare. It is important to establish its origin from a teratoma and rule out a primary melanoma elsewhere before considering the diagnosis of a primary ovarian melanoma.

## REFERENCES

- [1] Shramana M, Bhawana AB. Malignant Transformation in a Mature Teratoma with Metastatic Deposits in the Omentum: A Case Report. *Case Rep Pathol*. 2012. doi:10.1155/2012/568062.
- [2] Hye S, Seong TM. Primary malignant melanoma arising in a cystic teratoma. *Obstet Gynecol Sci*. 2013;56:201-04.
- [3] Godoy HE, Kesterson JP, Kasznic a JM, Lele S. Malignant melanoma arising in mature cystic teratoma of the ovary. *Gynecol Oncol Case Rep*. 2011;2:14-5. doi: 10.1016/j.gynor.2011.10.007.
- [4] Sbitti Y, Fadoukhaïr Z, Kadirî H, Oukabli M, Essaïdi I, Kharmoum S, et al. Diagnostic challenge for ovarian malignant melanoma in premenopausal women: Primary or metastatic? *World J Surg Oncol*. 2011;9:65.

- [5] Gupta D, Deavers MT, Silva EG, Malpica A. Malignant melanoma involving the ovary: a clinicopathologic and immunohistochemical study of 23 Cases. *Am J Surg Pathol*. 2004;28:771-80.
- [6] Liberati F, Maccio T, Ascani S, Farabi R, Lancia D, Peciarolo A, et al. Primary malignant melanoma arising in an ovarian cystic teratoma. *Acta Oncol*. 1998;37:381-83.
- [7] Moehrl M, Fischbach H, Nuessle B, Rassner G. Primary malignant melanoma arising in a cystic necrotic ovarian teratoma. *Eur J Obstet Gynecol Reprod Biol*. 2001;99:268-71.
- [8] Lee S, Kim HJ, Chon RG, Kim A, Kim HB. Primary malignant melanoma arising in an ovarian mature cystic teratoma -a case report and literature review. *Korean J Pathol*. 2011;45:659-64.
- [9] Andrews HR. Primary melanoticsarcoma of the ovary. *Trans Obstet Soc*. 1901;43:228-31.
- [10] Ueda Y, Kimura A, Kawahara E, Kitagawa H, Nakanishi I. Malignant melanoma arising in a dermoid cyst of the ovary. *Cancer*. 1991;67:3141-45.
- [11] Harris A, Blumenthal N. Metastatic malignant melanoma arising in the ovary: A case report and review of the literature. *Open J Obstet Gynecol*. 2013;3:7-9.
- [12] Boughton RS, Hughmanick S, Marin-Oadilla M. Malignant melanoma arising in an ovarian cystic teratoma in pregnancy. *J Am Acad Dermatol*. 1987;17:871-75.

**PARTICULARS OF CONTRIBUTORS:**

1. Professor, Department of Pathology, Kasturba Medical College, Manipal, Karnataka, India.
2. Assistant Professor, Department of Pathology, Kasturba Medical College, Manipal, Karnataka, India.
3. Associate Professor, Department of Radiodiagnosis & Imaging, Kasturba Medical College, Manipal, Karnataka, India.

**NAME, ADDRESS, E-MAIL ID OF THE CORRESPONDING AUTHOR:**

Dr. Gauri Salgaonkar Ayachit,  
Assistant Professor, Department of Pathology, Kasturba Medical College, Manipal, Karnataka, India.  
E-mail : dcgauri2477@gmail.com

Date of Submission: **Dec 21, 2014**Date of Peer Review: **Feb 08, 2015**Date of Acceptance: **Feb 21, 2015**Date of Publishing: **Apr 01, 2015****FINANCIAL OR OTHER COMPETING INTERESTS:** None.